

## ORIGINAL ARTICLE

**Surgical Outcomes of Spondylolisthesis Comparing Open Lumbar Interbody Fusion with or without Posterior Lumbar Interbody Fusion (PLIF) Cage**

\*Md Moshir Rahman<sup>1</sup>, K.M. Ziaur Rahman<sup>2</sup>, Md Mustahizur Rahman<sup>3</sup>, Ahsanul Haque<sup>4</sup>

DOI : <https://doi.org/10.47648/jmsr.2023.v3502.04>

**Abstract:**

*Objective: This study aimed to evaluate the surgical outcomes of spondylolisthesis by comparing open lumbar interbody fusion with or without the use of a posterior lumbar interbody fusion (PLIF) cage. Method: A total of 15 cases of PLIF were performed between May 2023 and December 2024 at Holy Family Red Crescent Medical College Hospital, Neurosurgery Unit 2. The study included 8 male and 7 female patients aged 36–68 years. Surgical outcomes of lumbar interbody fusion with or without PLIF cages in spondylolisthesis cases were assessed using PROMIS scores. Each patient underwent comprehensive follow-up and neurological assessment. Result: Complications included one superficial wound infection, one minor cerebrospinal fluid (CSF) leak successfully managed intraoperatively, and one case of deep vein thrombosis. Larger cages (1 mm larger) demonstrated efficacy in reducing cage subsidence. Conclusion: PLIF is effective for spondylolisthesis, yielding good outcomes with cage usage. Larger cages are associated with a decreased incidence of subsidence and dislodgement.*

**Key words:** Spondylolisthesis, Lumbar spinal fusion, PLIF cage

1. Associate Professor and Head, Department of Neurosurgery, Holy Family Red Crescent Medical College
2. Registrar, Department of Neurosurgery, Holy Family Red Crescent Medical College Hospital
3. Assistant Professor, Department of Orthopaedics, Holy Family Red Crescent Medical College
4. Resident Doctor, Department of Neurosurgery, Holy Family Red Crescent Medical College Hospital

\*Corresponding author: [dr.tutul@yahoo.com](mailto:dr.tutul@yahoo.com)

**Introduction**

Spondylolisthesis, a degenerative spinal disorder, is characterized by the forward slippage of a vertebra over the one below it. This condition often leads to debilitating symptoms such as chronic back pain, radiculopathy, and functional limitations, requiring surgical intervention in severe cases<sup>1,2</sup>.

Posterior lumbar interbody fusion (PLIF) is a widely accepted surgical technique for addressing spondylolisthesis. It restores spinal stability, facilitates decompression, and enables neural foramen restoration through the use of interbody cages<sup>3,4</sup>. Interbody cages offer the added benefit of maintaining intervertebral height and promoting fusion, with studies demonstrating high success rates when appropriately sized cages are used<sup>5–7</sup>.

However, the improper use of cages may result in complications such as subsidence, dislodgement, or pseudoarthrosis<sup>8,9</sup>.

Assessing surgical outcomes has traditionally relied on clinician-reported metrics, but patient-reported outcomes such as the PROMIS (Patient-Reported Outcomes Measurement Information System) score are increasingly emphasized for a holistic evaluation<sup>10,11</sup>. PROMIS enables the measurement of domains including physical function, pain interference, and mental health, and has been validated as an essential tool in spine surgery<sup>12</sup>.

Despite the benefits of PLIF, limited research compares outcomes of lumbar interbody fusion with or without the use of interbody cages in spondylolisthesis. This study bridges this gap by

evaluating PROMIS-based functional outcomes, complications, and cage-related factors in patients treated with PLIF.

### Methodology:

This retrospective, comparative study evaluated the surgical outcomes of spondylolisthesis treated with lumbar interbody fusion with and without PLIF cages. The study was conducted at Holy Family Red Crescent Medical College Hospital, Neurosurgery Unit 2, between May 2023 and December 2024.

Two groups of patients were compared:

1. PLIF Cage Group: 15 patients who underwent lumbar interbody fusion with PLIF cages.
2. No-Cage Group: 15 patients who underwent lumbar interbody fusion without PLIF cages.

Inclusion criteria:

- Patients aged 36–68 years.
- Diagnosed with Grade I or II spondylolisthesis based on Meyerding's classification.
- Failure of conservative management for at least 6 months.

Exclusion criteria:

- Prior spinal surgeries.
- Severe comorbidities (e.g., uncontrolled diabetes or cardiac conditions).

**Surgical Technique:** Both groups underwent posterior lumbar interbody fusion. The PLIF Cage Group had interbody cages placed during surgery, while the No-Cage Group relied solely on bone grafting for interbody fusion.

**Outcome Measures:**

1. PROMIS Scores: Collected preoperatively, at 1 month, and at 6 months postoperatively, focusing on physical function and pain interference domains
2. Fusion Rates: Assessed via radiographs or CT scans at 6 months.
3. Complications: Monitored for wound infection,

CSF leaks, DVT, subsidence, and pseudoarthrosis.

**Statistical Analysis:** PROMIS scores were analyzed using paired and independent t-tests. Fusion rates and complications were analyzed with chi-square tests. Statistical significance was defined as  $p < 0.05$ .

### Results:

The demographic and baseline characteristics were comparable between the PLIF cage group and the no-cage group. The mean age was  $54.2 \pm 9.6$  years in the cage group and  $53.8 \pm 8.9$  years in the no-cage group. Both groups had a similar distribution of gender (8:7 vs. 9:6 male-to-female ratio) (table 1) and radiological grading (Grade I:Grade II ratio of 10:5 vs. 11:4). All patients were followed up for a period ranging from 6 to 18 months. Preoperatively, there was no significant difference in PROMIS scores between the two groups ( $41.5 \pm 6.2$  vs.  $42.3 \pm 5.8$ ;  $p = 0.75$ ). However, at one month postoperatively, the cage group demonstrated significantly better PROMIS scores ( $51.8 \pm 4.3$  vs.  $47.2 \pm 5.1$ ;  $p = 0.03$ ), and this difference remained significant at six months ( $63.2 \pm 5.1$  vs.  $56.8 \pm 6.4$ ;  $p = 0.02$ ).

Radiologically, fusion was achieved in 87% (13/15) of patients in the cage group compared to 60% (9/15) in the no-cage group at six months, which was statistically significant ( $p = 0.04$ ). Complication rates were overall comparable between the groups, although mechanical complications were more frequent in the no-cage group. Subsidence occurred in 3 patients in the no-cage group versus 1 in the cage group, while pseudoarthrosis was observed only in the no-cage group ( $n = 2$ ). Other complications such as superficial infections, CSF leaks, and deep vein thrombosis occurred at similar rates in both groups.

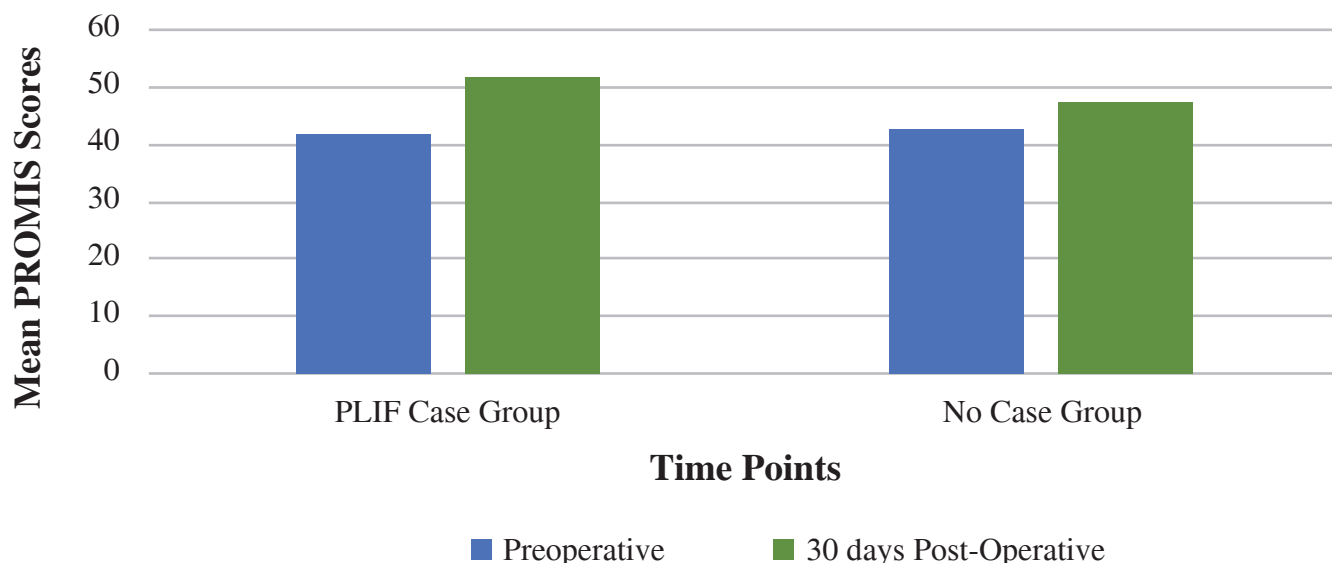
**Key Findings:**

- PROMIS Scores: The PLIF Cage Group showed better functional recovery and pain reduction at both 1-month and 6-month follow-ups.
- Fusion Rates: At 6 months, the PLIF Cage Group

had significantly higher fusion rates compared to the No-Cage Group.

- Complications: The No-Cage Group had a higher incidence of subsidence and pseudoarthrosis, indicating structural instability.

### Comparative PROMIS Scores of Two Groups



**Figure 1:** Comparative PROMIS Scores of Two Groups

The bar diagram represents the mean PROMIS scores for the PLIF Cage Group and No-Cage Group across two time points:

Preoperative: PLIF Cage Group: 41.5 and No-Cage Group: 42.3

1-Month Post-operative: PLIF Cage Group: 51.8 and No-Cage Group: 47.2

**Key Observations:** The PLIF Cage Group consistently outperformed the No-Cage Group in PROMIS scores at all time points.

The difference in scores was particularly significant at 30 days post-operation.

#### Discussion:

This study demonstrates that PLIF is a reliable and effective surgical option for treating spondylolisthesis, with significant improvements in PROMIS scores supporting its role in alleviating pain and restoring functional capacity. Our findings align with existing literature that highlights PLIF's efficacy in achieving neural decompression and

stable fusion<sup>3,13</sup>.

The use of larger interbody cages emerged as a critical factor in reducing the risk of subsidence. Previous biomechanical studies have shown that larger cages distribute axial loads over a broader surface area, thereby mitigating endplate damage and enhancing stability<sup>5,14,15</sup>. These findings are consistent with other clinical studies that advocate for tailored cage dimensions to optimize surgical outcomes<sup>6,16</sup>.

Despite these promising results, complications such as wound infections and CSF leaks remain a concern. The observed complication rate of 20% is comparable to prior reports, where rates ranged between 15–25%<sup>8,17,18</sup>. Advances in intraoperative techniques, including dural repair methods and infection prevention strategies, could further reduce these rates in the future.

This study highlights the utility of PROMIS scores in capturing patient-centered outcomes, particularly in the domains of physical function and

pain interference. The incorporation of PROMIS into routine practice has been shown to enhance the assessment of surgical success and patient satisfaction<sup>10,11,19</sup>.

However, this study is not without limitations. The small sample size and the lack of a randomized control group limit the generalizability of the findings. Future studies with larger, multicenter cohorts are warranted to confirm the observed trends and refine the application of PLIF techniques<sup>20</sup>.

### Conclusion:

PLIF is an effective surgical technique for spondylolisthesis, with interbody cages enhancing stability and reducing complications such as subsidence. Larger cages, tailored to patient anatomy, improve outcomes by providing better load distribution. The integration of PROMIS scores into clinical practice offers valuable insights into patient recovery and surgical success.

### References:

1. Song, Deyong et al. "Comparison of posterior lumbar interbody fusion (PLIF) with autogenous bone chips and PLIF with cage for treatment of double-level isthmic spondylolisthesis." *Clinical neurology and neurosurgery* vol. 138 (2015): 111-6. doi:10.1016/j.clineuro.2015.08.012
2. Zhang, Shengtao et al. "Double-level lumbar spondylolysis and spondylolisthesis: A retrospective study." *Journal of orthopaedic surgery and research* vol. 13,1 55. 16 Mar. 2018, doi:10.1186/s13018-018-0723-3
3. Okuda, Shin'ya et al. "Risk factors for adjacent segment degeneration after PLIF." *Spine* vol. 29,14 (2004): 1535-40. doi:10.1097/01.brs.0000131417.93637.9d
4. Ahmadi Pirshahid, Ali et al. "Morselized corticocancellous bone as primary graft for posterior lumbar fusion: a systematic review and meta-analysis." *European spine journal : official publication of the European Spine Society, the European Spinal Deformity Society, and the European Section of the Cervical Spine Research Society* vol. 34,3 (2025): 925-934. doi:10.1007/s00586-024-08628-5
5. Yamagishi, Akira et al. "The Influence of Titanium-coated Polyetheretherketone Cages in Fusion Status after Posterior Lumbar Interbody Fusion with Cortical Bone Trajectory Screw Fixation." *World neurosurgery* vol. 183 (2024): e201-e209. doi:10.1016/j.wneu.2023.12.056
6. Capo, Gabriele et al. "Lateral-PLIF for spinal arthrodesis: concept, technique, results, complications, and outcomes." *Acta neurochirurgica* vol. 166,1 123. 7 Mar. 2024, doi:10.1007/s00701-024-06024-y
7. Pitzen, T et al. "The effect of posterior instrumentation following PLIF with BAK cages is most pronounced in weak bone." *Acta neurochirurgica* vol. 144,2 (2002): 121-8; discussion 128. doi:10.1007/s007010200014
8. Lam, Fred C et al. "The effects of design and positioning of carbon fiber lumbar interbody cages and their subsidence in vertebral bodies." *Journal of spinal disorders & techniques* vol. 25,2 (2012): 116-22. doi:10.1097/BSD.0b013e31820ef778
9. Krammer, M et al. "Resistance of the lumbar spine against axial compression forces after implantation of three different posterior lumbar interbody cages." *Acta neurochirurgica* vol. 143,12 (2001): 1217-22. doi:10.1007/s007010100017
10. Buttermann, Glenn R et al. "Interbody device endplate engagement effects on motion segment biomechanics." *The spine journal : official journal of the North American Spine Society* vol. 9,7 (2009): 564-73. doi:10.1016/j.spinee.2009.03.014
11. Chutkan, Norman B et al. "Effects of facetectomy and crosslink augmentation on motion segment flexibility in posterior lumbar interbody fusion." *Spine* vol. 33,22 (2008): E828-35. doi:10.1097/BRS.0b013e318183bb6d
12. Ghogawala, Zoher et al. "Laminectomy plus Fusion versus Laminectomy Alone for Lumbar Spondylolisthesis." *The New England journal of medicine* vol. 374,15 (2016): 1424-34. doi:10.1056/NEJMoa1508788
13. Vasudeva, Viren S et al. "Fusion for Lumbar

Stenosis With Spondylolisthesis: Results From 2 Randomized Trials.” *Neurosurgery* vol. 79,2 (2016): N18-20. doi:10.1227/01.neu.0000489889.10464.a7

14. Försth, Peter et al. “A Randomized, Controlled Trial of Fusion Surgery for Lumbar Spinal Stenosis.” *The New England journal of medicine* vol. 374,15 (2016): 1413-23. doi:10.1056/NEJMoA1513721

15. Pitzen, T et al. “Die Primärstabilität zweier PLIF-Techniken--Ein biomechanischer In-vitro-Vergleich” [Primary stability of 2 PLIF (posterior lumbar interbody fusion)--a biomechanical in vitro comparison]. *Zeitschrift für Orthopädie und ihre Grenzgebiete* vol. 137,3 (1999): 214-8. doi:10.1055/s-2008-1037396

16. Oda, Itaru et al. “Types of spinal instability that require interbody support in posterior lumbar reconstruction: an in vitro biomechanical investigation.” *Spine* vol. 28,14 (2003): 1573-80.

17. Mihara, Hisanori et al. “The biomechanical effects of spondylolysis and its treatment.” *Spine* vol. 28,3 (2003): 235-8. doi:10.1097/01.BRS.0000042226.59713.0E

18. Hongo, Michio et al. “Junction kinematics between proximal mobile and distal fused lumbar segments: biomechanical analysis of pedicle and hook constructs.” *The spine journal : official journal of the North American Spine Society* vol. 9,10 (2009): 846-53. doi:10.1016/j.spinee.2009.06.019

19. Cheng, Boyle C et al. “Immediate biomechanical effects of lumbar posterior dynamic stabilization above a circumferential fusion.” *Spine* vol. 32,23 (2007): 2551-7. doi:10.1097/BRS.0b013e318158cdbe

20. Mandigo, Christopher E et al. “Posterior dynamic stabilization of the lumbar spine: pedicle based stabilization with the AccuFlex rod system.” *Neurosurgical focus* vol. 22,1 E9. 15 Jan. 2007, doi:10.3171/foc.2007.22.1.9



This work is licensed under a Creative Commons Attribution 4.0 License. You are free to copy, distribute and perform the work. You must attribute the work in the manner specified by the author or licensor.